

REVIEW

Open Access

Efficacy of alpha1-antitrypsin augmentation therapy in conditions other than pulmonary emphysema

Ignacio Blanco^{1*}, Beatriz Lara² and Frederick de Serres³

Abstract

Up to now alpha 1-antitrypsin (AAT) augmentation therapy has been approved only for commercial use in selected adults with severe AAT deficiency-related pulmonary emphysema (i.e. Pi*ZZ genotypes as well as combinations of Z, rare and null alleles expressing AAT serum concentrations <11 μmol/L). However, the compassionate use of augmentation therapy in recent years has proven outstanding efficacy in small cohorts of patients suffering from uncommon AAT deficiency-related diseases other than pulmonary emphysema, such as fibromyalgia, systemic vasculitis, relapsing panniculitis and bronchial asthma. Moreover, a series of preclinical studies provide evidence of the efficacy of AAT augmentation therapy in several infectious diseases, diabetes mellitus and organ transplant rejection. These facts have generated an expanding number of medical applications and patents with claims for other indications of AAT besides pulmonary emphysema. The aim of the present study is to compile and analyze both clinical and histological features of the aforementioned published case studies and reports where AAT augmentation therapy was used for conditions other than pulmonary emphysema. Particularly, our research refers to ten case reports and two clinical trials on AAT augmentation therapy in patients with both AAT deficiency and, at least, one of the following diseases: fibromyalgia, vasculitis, panniculitis and bronchial asthma. In all the cases, AAT was successfully applied whereas previous maximal conventional therapies had failed. In conclusion, laboratory studies in animals and humans as well as larger clinical trials should be, thus, performed in order to determine both the strong clinical efficacy and security of AAT in the treatment of conditions other than pulmonary emphysema.

Introduction

Alpha1-antitrypsin (AAT) deficiency is an autosomal, codominant genetic disorder, characterized by the polymerization of abnormal, misfolded proteins in the rough endoplasmic reticulum of hepatocytes and, secondarily, a decreased concentration and activity of AAT in blood and tissues. Although several degrees of AAT deficiency are quite common worldwide, severe deficiency (i.e. AAT serum levels below 11 μmol or 50 mg/dL) represents a rare condition affecting 1 per 2,000-5,000 Caucasian individuals of Western European origin, with about a quarter or half of them developing clinically significant diseases [1,2].

Human alpha-1 antitrypsin (AAT), also called alpha-1 proteinase inhibitor (PI), and SERPINA1 (Serine Protease Inhibitor, clade A, member 1), is a 394-amino acid, circulating glycoprotein with a molecular weight of 52-kDa. AAT is medium sized and globular in shape (6.7 × 3.2 nm), water soluble and diffusible into different tissues, with an average of 4-5 day life span in circulating blood. AAT is mainly secreted by hepatocytes (~80%) and, to a minor extent, by monocytes, pancreatic islets, lung alveolar cells and colonic enterocytes, reaching high mean concentrations in plasma (1-2 g/L). Eighty percent of plasmatic protein diffuses into different body tissues and approximately 10% reaches most biological fluids [3].

Extensive data show that the major function of AAT is the inhibition of over-expressed neutrophil elastase and other serine proteinases (i.e. proteinase-3, myeloperoxidase and cathepsin G from neutrophils, trypsin and

* Correspondence: ignablanco@yahoo.com

¹Biomedical Research Office (OIB-FICYT), Rosal, 7. 33009 Oviedo. Principality of Asturias, Spain

Full list of author information is available at the end of the article

chymase from mast cells, etc.) in order to maintain the physiological proteinase-antiproteinase balance [4-34]. Moreover, an increasing number of new inhibitory and non-inhibitory properties conferring to AAT outstanding anti-inflammatory, immunomodulatory and antimicrobial attributes have been discovered in later years, together with the fact that AAT activity is not only limited to lungs but also to most body tissues [35-38].

AAT gene has two alleles. Normal alleles are called M; thus, normal individuals have genotype MM. The most common severe deficiency allele is called Z (Glu342Lys); in clinical practice over 95% of severely deficiency patients have genotype ZZ (expressing 10-20% of serum AAT). The remaining 5% belongs to patients with genotype SZ and about 30 rare deficiency and null phenotypes, expressing 0-30% AAT serum levels. Most common diseases related to severe AAT-deficiency are pulmonary emphysema (found in around 3% of adults with COPD), liver cirrhosis (2.5% of children and 10-20% of PI*Z adult homozygotes), systemic vasculitis (7%) and relapsing panniculitis (0.1%) [3,39,40].

In 1987 the Food and Drug Administration (FDA) published the first guidelines on augmentation therapy with intravenous infusions of purified AAT obtained from human serum of adults suffering from moderate pulmonary emphysema (FEV1 30-65%) and severe AAT deficiency (i.e. PI*ZZ genotypes and combinations of Z, rare and null alleles expressing AAT serum concentrations < 11 μ mol or 50 mg/dL) [41]. Taking into account scientific evidence and knowledge, the American Thoracic Society, the European Respiratory Society, the American College of Chest Physicians and the American Association for Respiratory Care recommend augmentation therapy for selected patients with lung emphysema. Augmentation therapy not only has been approved in the US but also in Germany, Canada, Italy, Spain, Austria, Ukraine, Argentina and Brazil, with similar criteria of use [3,42-52].

In the last years, preclinical studies in cells, animal models and small cohorts of humans provided initial evidence for the efficacy of AAT in several infectious diseases, diabetes mellitus, organ transplant rejection and other possible inflammatory diseases [38,53-60]. As a consequence, the number of medical applications and patents for other indications of AAT other than pulmonary emphysema is increasing <http://www.omnibio-pharma.com/development>. In this context, clinical observations describing the remarkable (even impressive) efficacy of the augmentation therapy in AAT deficiency patients with fibromyalgia, systemic vasculitis, panniculitis and bronchial asthma have also been reported [61-70]. According to Jenicek's statement on clinical case reporting, these observations should be taken into account: *"Although a case report has the weakest level of Evidence Based Medicine, sometimes an unusual case may become*

an "index case", and it may lead to the formulation of new hypothesis on diagnostic and therapeutic options" [71]. The aim of the present manuscript is to compile published case reports and small trials where augmentation therapy was provided, on a compassionate basis, to humans with disorders other than pulmonary emphysema and to discuss their results in the light of current knowledge on AAT deficiency-related disorders.

Methods

Firstly, a research on the MEDLINE database (1966-2010) was made using the generic terms: "alpha-1 antitrypsin", "alpha-1-proteinase inhibitor" and "alpha-1 antitrypsin deficiency" and combining them with one of the following key concepts: "augmentation therapy", "replacement therapy", "treatment". Afterwards, a more specific search was carried out adding to the previous terms one of the following terms: "infectious diseases", "inflammatory diseases", "associated diseases", ("NOT emphysema"), "fibromyalgia", "human immunodeficiency virus", "HIV", "panniculitis", "vasculitis", "bronchial asthma", "graft rejection", "diabetes", "influenza", "tuberculosis" and "anthrax". We also consulted EMBASE Excerpta Medica, SciVerse Scopus and the Cochrane Library databases in order to search for abstracts of similar types of papers, as well as bibliographic references of previously retrieved articles, authors' databases and reviews from several experts on this topic.

Only reports related to human beings were selected. Studies on augmentation therapy for pulmonary emphysema have not been included in the present analysis, considering this topic to be out of the scope of the present manuscript.

Results

Ten case reports [61-68] and two clinical trials [69,70] have been found on intravenous AAT augmentation therapy in 12 patients with both AAT deficiency and one of the following diseases: vasculitis, panniculitis, fibromyalgia and bronchial asthma. Ten of these 12 treated patients had genotype PI*ZZ [61-68] and the remaining 2, PI*MZ.[69,70].

1. Vasculitis

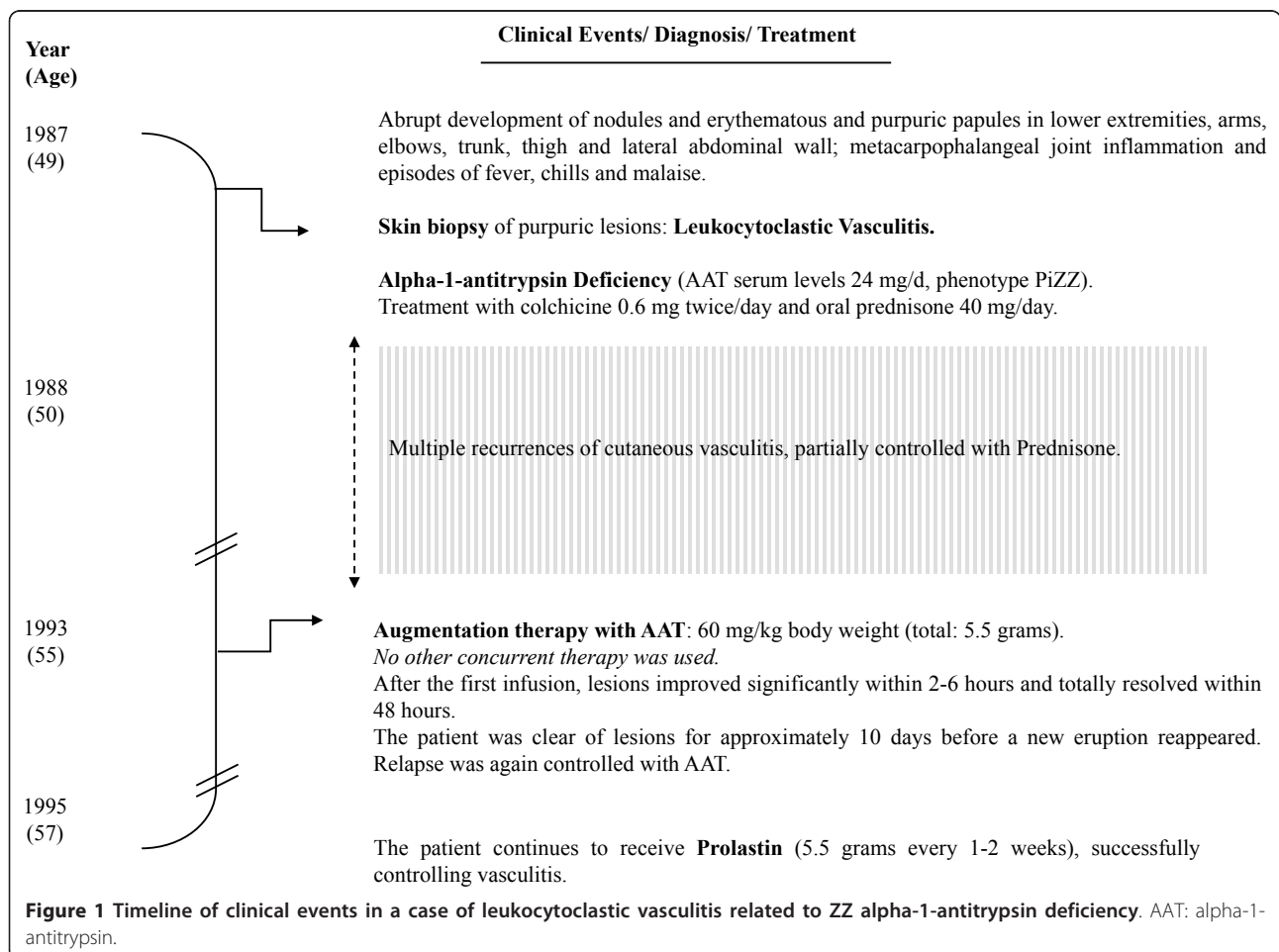
In 1995 Dowd et al (University of Louisville School of Medicine, Louisville, Kentucky) reported a case of to "a 49-year-old man, with a PI*ZZ genotype and AAT serum of 24 mg/d, suffering from extensive cutaneous leukocytoclastic vasculitis, with multiple recurrences partially controlled with colchicine, prednisone, plasma infusions and plasma-exchange therapy" [61]. Authors describe the occurrence of repetitive outbreaks of fever, chills, purpuric papules and nodules in lower extremities, arms, face, trunk, hands and the lateral abdominal

wall, provoking large vitiligo areas in elbows, knees, dorsal hand and pretibial surfaces. A biopsy skin sample showed alterations related to leukocytoclastic vasculitis (i.e. inflammatory involvement of medium and small vessels, red blood cell extravasations, edema and clear neutrophilic invasion with leukocytoclasia (disrupted neutrophils). The results of a complete blood cell count, serum multiphasic analysis and urinalysis were normal. Studies with normal or negative findings included assays for antinuclear antibody, antibodies to extractable nuclear antigen, antinuclear DNA, complement levels and hepatitis B surface antigen. The chest roentgenogram was within normal limits as well as pulmonary function tests. Five years later, the patient displayed a “dramatic response after 1 dose of Prolastin® (60/mg/Kg), with improvement <6 hrs, and total resolution <48 hrs” and “good control with long-term augmentation therapy (60/mg/Kg)/1-2 weeks” (Figure 1).

2. Panniculitis

From 1987 to 2010 seven cases of AAT deficiency-related refractory relapsing panniculitis, treated with

AAT as the last resource, were published [62-67]. The two first cases were reported by clinicians in the Mayo Clinic, Rochester, Minn, in 1987 [62]. Ten years later, 2 other cases were reported by the Northwestern University Medical School of Chicago [63,64], and, from 2002, 3 new cases (1 each from the UK [65], Norway [66] and Germany [67]) were reported by several European authors. All these 7 patients were females with genotypes PI*ZZ. Their mean AAT serum concentrations were 29 mg/dL (range: 20-46), and their mean age 44 years (range: 21-65). In all the cases sequential infusions of AAT were applied after the repetitive failure of conventional therapies [i.e. antibiotics (doxycycline, minocycline, cloxacillin and nafcilina), dapsone, systemic corticosteroids, ciclofosfamida, chloroquine, nitrogen mustard, plasma infusions, plasmapheresis, etceteras]. As a whole, skin samples showed a high expression of cell components, being neutrophil invasion the most relevant finding. They also disclosed the variable presence of scattered monocytes, lymphocytes and macrophages, areas of tissue destruction, fibroblasts and fibrosis, inflammation and rupture of fibrous septa



between fat lobules, liquefactive necrosis, elastin breakdown, scars, fistulas and ulcers. In the only case where Z polymers were investigated, they were demonstrated to appear both in active lesions and surrounding non-inflamed tissues [67]. The response to AAT infusions

was uniformly positive in all the cases, being described in some reports as “dramatic”, “very-high and rapid”, “life-saving”, etc. (Figure 2).

In the same context, the results of two liver transplants in PI*ZZ patients with end-stage liver cirrhosis

Author, Year [reference] Source	Sex (years) Genotype (AAT serum in mg/dL)	Clinical data	Effect of augmentation therapy
Smith et al, 1987 [62] Rochester, US	Case 1. F (65). ZZ (40)	Extensive ulcerative relapsing panniculitis requiring hospitalization	After the failure of Indomethacin, Prednisone, Azathioprine, Ketoconazole and Dapsone, a single infusion of AAT (60 mg/Kg/week) was applied in 2 severe recurrences, with significant clinical efficacy.
Smith et al, 1987 [62] Rochester, US	Case 2. F (36). ZZ (20)	Extensive ulcerative relapsing panniculitis requiring hospitalization	After the failure of Prednisone and Dapsone, 7 weekly infusions of AAT were successfully applied together with Dapsone and Prednisone.
Furey et al. 1996 [63] Chicago, US.	Case 3. F (62). ZZ. (24)	Extensive ulcerative relapsing panniculitis with massive edema (in legs, thighs and abdomen) requiring hospitalization	A single infusion of AAT (60 mg/ Kg) was provided. The response was dramatic. Within 24 hours, the patient could walk; and after 3 weekly infusions, both massive edema and panniculitis were resolved.
O’Riordan et al, 1997 [64] Chicago, US	Case 4. F (62). ZZ (23)	Severe ulcerative relapsing panniculitis	Panniculitis was completely resolved with 3 weekly doses of IV AAT (60/mg/Kg). Skin lesions recurred 6 months later but were resolved with 2 additional infusions, once levels of AAT were over 50 mg/dL.
Chowdhury et al 2002 [65] Cardiff, UK.	Case 5. F (33). ZZ (46)	Rapidly progressive panniculitis, septic shock and multiple life-threatening complications	Augmentation therapy was life-saving. Prolastin® quickly reduced inflammation within 24 hours. Since then, the patient has been feeling well, inflammation-free, under a treatment of 6 g/ week of Prolastin®.
Kjus T et al, 2003 [66]. Oslo, Norway	Case 6. F (21). ZZ (30)	Ulcerated chronic relapsing panniculitis.	After the failure of dapsone and doxycycline, the patient was successfully treated with i.v. infusions of Prolastin® (60/mg/Kg) once a week. “All lessons resolved within 2 days; reappeared after 4 weeks, and again disappeared 1-2 days after Prolastin®. At present, well controlled with infusions every 4th week”
Gross B [67]. 2009. Frankfurt, Germany.	Case 7. F (31). ZZ (22)	Ulcerated relapsing panniculitis. <i>Z-type AAT polymers were found in skin, supporting the hypothesis of the pro-inflammatory role of polymers.</i>	The long-term use of intravenous AAT augmentation therapy (Prolastin®) during 3 years reduced both the frequency and severity of panniculitis.

Figure 2 Demographic and clinical data of 7 patients with relapsing panniculitis associated to ZZ alpha-1-antitrypsin deficiency treated with alpha-1-antitrypsin augmentation therapy. F: female. AAT: alpha-1-antitrypsin.

and AAT deficiency-related panniculitis will be summarized. In both cases, a rapid and steady control of panniculitis was observed after the replacement of each damaged liver by a new efficient organ, restoring AAT serum levels back to normal. The first case was reported in 1997 by O'Riordan et al. (Northwestern University Medical School, Chicago, IL, USA) [64]. Authors observed evolution in "a 53-year old man...ZZ (AAT: 17 mg/100 ml)...with end-stage liver cirrhosis and relapsing panniculitis... [who] received a liver transplant. His new phenotype was PI*MM... and serum AAT of 153 mg/dL. One month after...a complete resolution of the skin lesions" was noticed.

The second case was reported by Fernandez-Torre et al. from the Hospital Juan Canalejo, La Coruña, Spain, in 2009 [72]. On the contrary, authors noticed alterations in "A 56-year-old MM patient [who] acquired a ZZ phenotype after a liver transplant for alcoholic liver cirrhosis. Subsequently, he developed cirrhosis and panniculitis. Liver transplantation was again performed, with complete resolution of the skin lesions and restoration of AAT serum levels (from 28 to 270 mg/dl)...11 months later he remains asymptomatic".

In the same context, de Oliveira et al. (São Paulo, Brazil) published in 2004 the case of a 23-year-old patient with extensive, ulcerative relapsing panniculitis, and AAT serum levels of 22 mg/dL and phenotype ZZ [73]. The patient was treated with 16 sessions of plasma exchange therapy, with cutaneous lesions clinically controlled after five sessions. AAT increased to 60 mg/dL after the first session, slowly decreasing to initial levels in approximately 15 days until the next plasma infusion (when AAT levels increased again and, thus, relapses were promptly controlled). This case shows many similarities with the first report on the use of plasma exchange therapy in panniculitis, made in 1986 by Viraben et al. [74], who used fresh plasma every other day for 2 weeks, with dramatic effectiveness. Both authors consider plasma exchange as an effective therapeutic alternative for unresponsive patients to conventional treatments, thus highlighting the necessity of further studies with a larger number of individuals.

3. Fibromyalgia

Up to date three cases have been reported by Blanco et al. (Hospital Valle del Nalón, Principality of Asturias, Spain) [68,69].

Cases 1 and 2 were reported in 2004 [68]. In the early nineties two PI*ZZ Spanish sisters with severe fibromyalgia started AAT replacement therapy. During the next 3 and 5 years, respectively, they both experienced a rapid, progressive and constant control of fibromyalgia symptoms. However, a commercial shortage of AAT by

1998 led to the annual interruption of infusions for 4-6 consecutive months during 5 years. As a result, fibromyalgia symptoms recurred during infusion interruption and disappeared completely whenever infusions were resumed. Currently, both patients are regularly treated with Prolastin[®], and do not have fibromyalgia symptoms anymore (Figure 3).

Case 3 was reported in 2010 [69]. In 2004 a patient with both AAT deficiency (MZ) and severe fibromyalgia/CFS (Chronic Fatigue Syndrome) participated in a trial with AAT-intravenous augmentation therapy after the failure of conventional therapies. Since then, the patient has experienced a very good clinical response (Figure 4).

At present, the 3 patients continue to be under long-term AAT augmentation therapy with successful results.

4. Bronchial asthma

In 2008, Blanco I, et al. (Hospital Valle del Nalón, Asturias, Spain) reported the case of a Caucasian 27-year old woman, working as a cleaner, who started to suffer from recurrent dyspnoea, wheezing, cough and chest tightness [70]. A totally reversible and variable spirometric airflow limitation was evidenced, and she was diagnosed with bronchial asthma (Figure 5). In the following years, she was also diagnosed with nasal polyps as well as Aspirin-Sensitive Asthma (ASA). Isoelectric-focusing and nephelometry showed that the patient had a deficient phenotype MZ with intermediate low AAT serum concentrations. On the other hand, PCR genotyping sequenced exons II-V of the AAT gene, diagnosing a genotype M₃Z. The results of several studies to rule out other conditions, mimicking or worsening bronchial asthma, were either normal or negative except for immune hyperthyroidism. The patient was firstly treated with Carbimazole and later with radioisotope therapy (causing iatrogenic hypothyroidism but easily managed with Levothyroxine). However, asthma persisted with frequent at night symptoms, daily attacks of dyspnoea and limited physical exertion. As pulmonary function significantly worsened due to asthma attacks, the patient had to use frequently the emergency medical services and even was admitted to hospital in several occasions. She was prescribed long-term prednisone tablets (15-30 mg/day). However, asthma continued to be out of control and bronchial obstruction, permanent. Moreover, significant side effects of glucocorticoid drugs appeared in the following months. As a consequence, the patient experienced severe limitation of her physical capacity which negatively affected her mental state and social and personal life. The results of a computerized axial tomography of the chest to rule out pulmonary emphysema and other intercurrent complications were within normal limits. Due to the unfavourable clinical

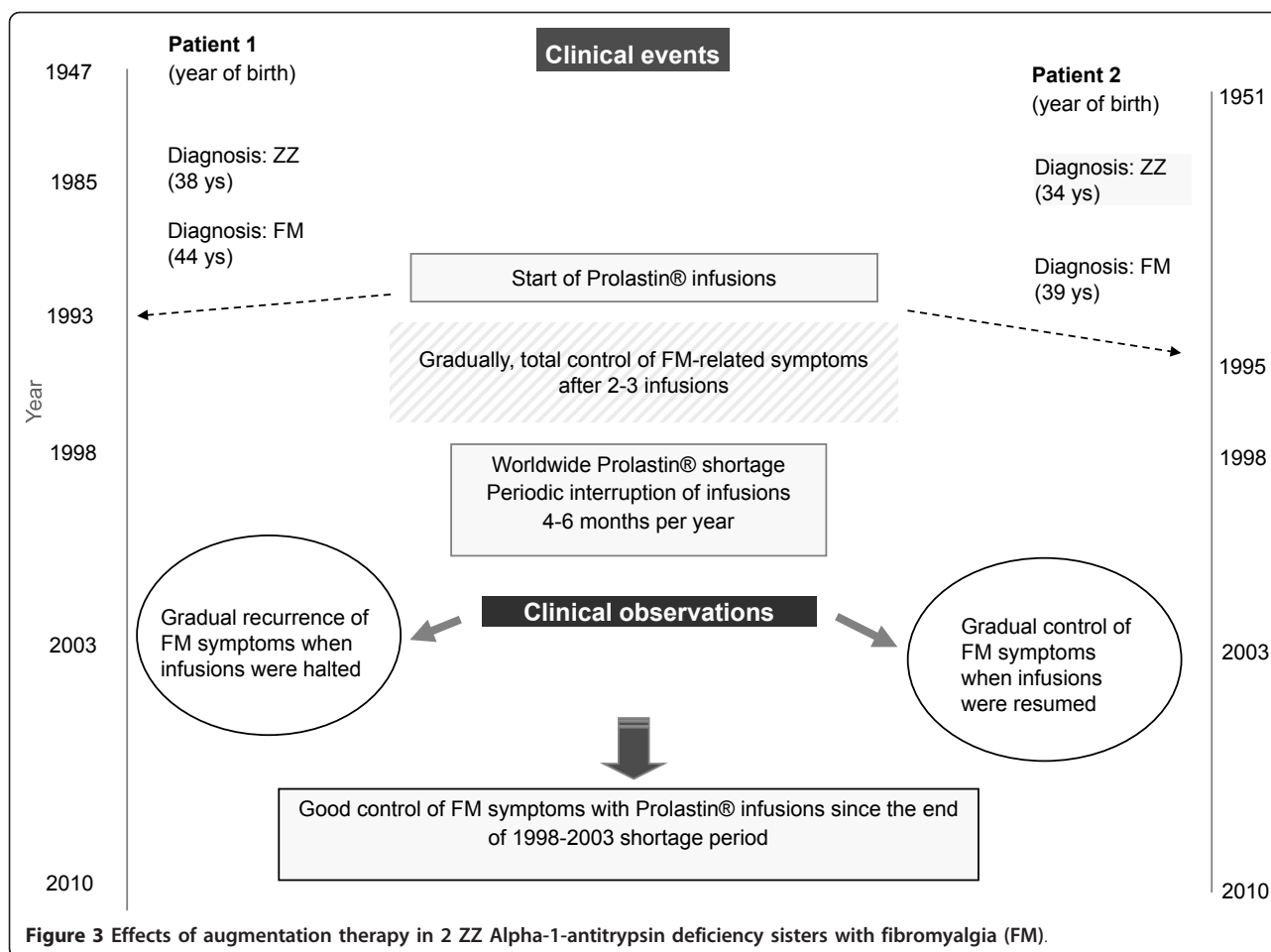
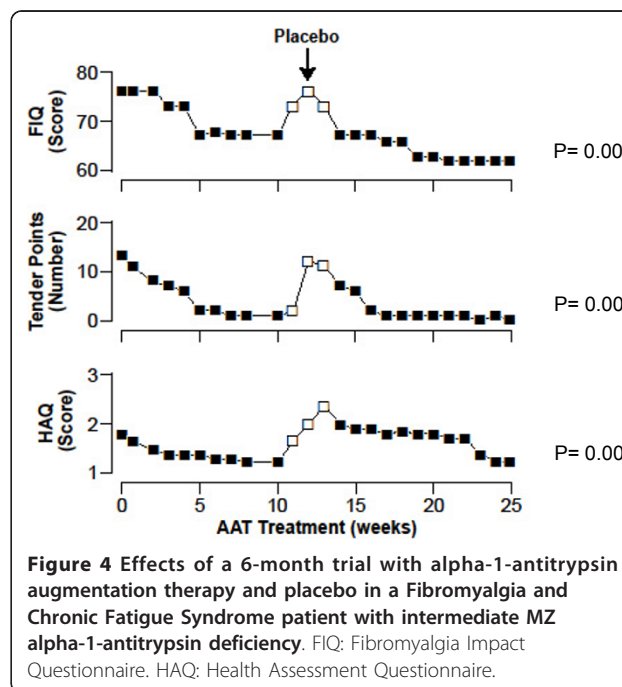


Figure 3 Effects of augmentation therapy in 2 ZZ Alpha-1-antitrypsin deficiency sisters with fibromyalgia (FM).

evolution of the patient, doctors tried a therapeutic trial with AAT augmentation therapy (60 mg/Kg/week dose for the first two weeks and 120 mg/biweekly for 7 months). As the results of the trial were significantly favourable, the treatment continued. The continuous administration of AAT infusions stopped the decline in lung function. In 1991-1994 (period 1) her FEV1 (expressed by mean and standard deviation) was equivalent to 69% (17); in 1995-2003 (period 2) it declined to 43% (5.14); and from 2004, once the AAT augmentation therapy started, to 2007 (period 3), it rose up to 52% (3.75). Statistical significance was found between period 1 and period 2 ($p = 0.000$), period 1 and period 3 ($p = 0.000$), and period 2 and period 3 ($p = 0.001$). As expected, the augmentation therapy increased the AAT serum levels of the patient, measured by nephelometry and expressed in mg/dL, from basal values of 0.78 (0.04) to 1.08 (0.10) pre-infusions and 2.61 (0.34) post-infusions. Moreover, AAT augmentation therapy significantly reduced the number of emergency visits and hospital admissions (22 emergency visits in 2001-2003 vs. 8 in 2004-2007; and 4 hospital admissions in



Year	Age	Diagnosis	Comorbidities & Events	Treatment							Asthma Attack Related		
				Long + Short-acting β_2 Agonists	Inhaled Corticosteroids	Montelukast	Oral theophylline	Oral prednisone (daily)	L-thyroxine	AAT infusion	Emergency Service Attention	Hospital Admission	
1989	27	Moderate persistent asthma		+	+ ^a							-	-
1993	31	Nasal polyps Aspirin-sensitive asthma (ASA)	Accelerated FEV1 declination	+	+ ^b	+	+					1	-
1999	37		Hyperthyroidism (radioisotope therapy) Resection of nasal polyps	+	+ ^b	+	+	+				3	1
2000	38		Yatrogenic hypothyroidism	+	+ ^b	+	+			+		5	2
2001	39		Steroid-induced Cushing's syndrome with osteoporosis development	+	+ ^b	+	+	+		+		6	-
2002	40	MZ-AAT deficiency		+	+ ^b	+	+	+		+		8	2
2003	41			+	+ ^b	+	+	+		+		8	2
2004	42		Daily oral prednisone removed Steroid-induced osteoporosis and Cushing's syndrome improvement	+	+ ^b	+	+			+		3	-
2005	43		Progressive improvement of quality of life Lung function declination stopped	+	+ ^b	+				+		2	-
2006	44		Decreased emergency service attentions and hospital admissions	+	+ ^b	+				+		1	-
2007	45			+	+ ^b	+				+		2	1 ^c

^a Medium dose
^b High dose
^c Pneumonia

Figure 5 Chronology of clinical events in an MZ-AAT patient with severe persistent asthma. AAT: Alpha1-antitrypsin. FEV1: Forced Expiratory Volume in 1 second.

2002-2003 vs. 1 in 2004-2007). The need for prednisone was also reduced shortly after the beginning of the augmentation therapy, facilitating the elimination of chronic corticoid side effects and progressively reducing the high score of Asthma Quality of Life (AQL) in 2003 from 10 to 3 points in 2007 (Figure 6).

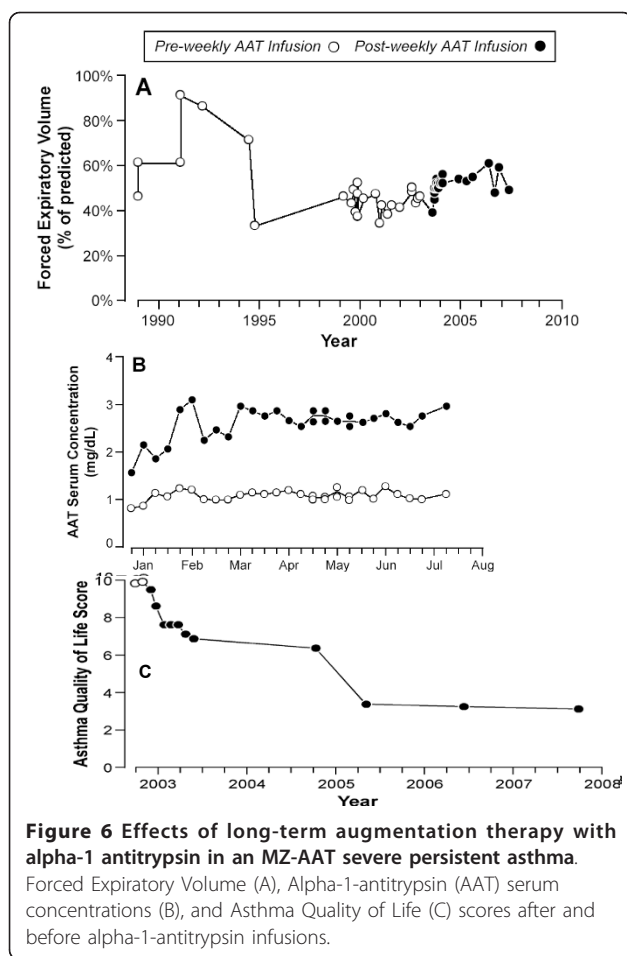
Conclusions

AAT deficiency is a congenital disorder with a remarkable variability in its clinical presentation [3]: some subjects can develop liver cirrhosis and others pulmonary emphysema; to a minor extent, they can also develop panniculitis, vasculitis, bronchial asthma or fibromyalgia; and more than one third of the remaining carriers can stay symptomless their entire life.

The 12 subjects mentioned in the present paper suffered from less common AAT deficiency-related diseases (i.e. leukocytoclastic vasculitis; relapsing panniculitis, fibromyalgia, and refractory asthma). All these patients

have in common AAT deficiency genotypes (10 ZZ, 2 MZ). Also they all experienced a positive response to intravenous AAT augmentation therapy, applied on a compassionate basis as the last resource after the repetitive failure of conventional therapies and the extremely difficult clinical control of AAT deficiency-related diseases (life-threatening in some cases).

The skin samples of the patient with leukocytoclastic vasculitis related to ZZ AAT deficiency showed acute and chronic inflammation. Neither anti-neutrophil cytoplasmic antibodies (ANCA) nor anti-neutrophil enzyme proteinase 3 (PR3-ANCA) antibodies were analyzed. Although the pathophysiological mechanisms of vasculitis have not been determined yet, they seem to be related to inflammatory mechanisms mediated by neutrophil invasion of the small and medium vessels. The excess of proteinase-3, not neutralized by AAT, could also play an important role in AAT deficiency subjects with antineutrophilic cytoplasmic antibody C-ANCA



positive vasculitis. Since AAT is a major inhibitor of PR3, the PR3-AAT imbalance in AAT deficiency-related vasculitis could lead to increased circulating levels of PR3 and trigger the synthesis of PR3-ANCA antibodies [39]. AAT deficiency-related vasculitis would be, therefore, restricted to PR3-ANCA-positive cases and not to less common occurrences of MPO-positive or ANCA-negative cases. On the other hand, patients with both vasculitis and AAT deficiency have been reported to have a reduced ability to bind PR3 released by neutrophils previously activated, thus promoting PR3-mediated proteolytic vessel damage. Actually, several findings show that the disease course of Wegener's granulomatosis (WG) is more severe when it is related to AAT deficiency than when it is not. This supports the hypothesis that AAT deficiency could trigger vasculitis by means of PR3-ANCA autoimmunity [40]. The role of circulating Z polymers, attacking the endothelial walls of blood vessels and promoting vasculitic responses, has not been determined yet nor whether all patients with manifestations of vasculitis and severe AAT deficiency could benefit from AAT augmentation therapy. However, the

administration of this glycoprotein seems to be logical for selected cases of AAT deficiency-related refractory vasculitis.

The pathophysiological mechanisms of panniculitis in AAT deficiency subjects have not been determined yet. As some hypotheses suggest an inflammatory process mediated by neutrophils invading the subcutaneous fat layer, the most logical mechanism seems to be the unopposed anti-inflammatory proteolytic damage by neutrophil-serine proteinases in the context of deficient serum levels of AAT [39]. In one of the aforementioned cases of the present study, Z polymers were found in both active lesions and surrounding non-inflamed tissues, suggesting a potential pro-inflammatory role of polymers in the development of panniculitis. The histological features of panniculitis, especially neutrophil invasion, could explain the rapid clinical resolution of inflammation with AAT augmentation therapy. Therefore, its application should be tried in cases which fail to respond to conventional therapeutic approaches.

Fibromyalgia syndrome is characterized by the central amplification of sensory impulses (central sensitization) causing autonomic, hormonal, immune and cytokine interactions and perturbations. Fibromyalgia can result from the disordered expression of inflammatory substances, amplified by genetic factors. Recent evidence indicates that fibromyalgia can be added to the list of AAT deficiency-related diseases. Main evidence elements include: **(I)** The short and long-term repetitive positive response to AAT augmentation therapy showed by the three aforementioned patients with both AAT deficiency and fibromyalgia [68,69]. **(II)** An epidemiological study showing a twofold higher frequency of PI*Z allele in fibromyalgia patients than in general population (4% vs. 2%), with a calculated prevalence of MZ, SZ and ZZ deficiency genotypes being 2-4 times higher in fibromyalgia patients than in general population [75]. Therefore, AAT deficiency should be considered as a predisposing factor for the development of early and severe onset of fibromyalgia in a subgroup of patients with AAT serum levels lower than normal (7% MZ, 0.5% SZ and 0.2% ZZ). **(III)** A case-control study showing plasma levels of MCP-1, VEGF and TNF-alpha significantly lower in AAT deficiency subjects with fibromyalgia than in controls [76]. **(IV)** A blinded immunohistochemical study of skin biopsies performed in 112 subjects (63 fibromyalgia vs. 49 controls) with AAT normal and deficient genotypes. The results showed a significantly increased number of mast cells in the dermis of fibromyalgia patients, with a proportion fibromyalgia/controls of about 5:1 cells per microscopic high power field ($p = 0.000$) [77]. Mastocytes positively stained with tryptase, AAT and PAR-2 antibodies as well as with a

kit receptor marker (CD117) and a cell activation marker (CD63), showing that about 50-80% of these mastocytes were activated. Remarkably, the skin samples of the 3 patients under long-term AAT augmentation therapy did not show any clinical fibromyalgia manifestations but also an increased number of dermal mast cells. Therefore, exogenous AAT could serve as a mast cell stabiliser and, as demonstrated in some laboratory studies, as a neutraliser of certain mast cells mediators (i.e. histamine and serine proteinases, such as tryptase and chymase) [17-19]. AAT augmentation therapy should be considered to treat selected cases of AAT deficiency-related refractory fibromyalgia not responding to conventional therapeutic measures, and larger trials are needed to determine the strong clinical efficacy of AAT in fibromyalgia patients.

Histological samples from airways were not collected in the case of the patient with bronchial asthma. However, it is worth noting that severe asthma is considered as an inflammatory airway disease related to sub-acute and chronic inflammation maintained by eosinophils, mastocytes, dendritic, epithelial and endothelial cells, basophiles, T lymphocytes, macrophages and neutrophils. Therefore, AAT could also play a determining anti-inflammatory role in counteracting the effects of released oxidants, cytokines, proteinases and other inflammation mediators. Precisely, the imbalance between elastase and AAT in asthmatic subjects has been already described as well as the relation of airway inflammation to abnormal high levels of active elastase, detected in patients' samples of induced sputum [78]. Neutrophil elastase has not only proteolytic properties but also acts as a powerful secretagogue. Particularly, recent evidence indicates the persistence of neutrophilic and eosinophilic inflammation in patients' airways with severe asthma, and the activation by neutrophil proteinases (i.e. elastase, cathepsin G and proteinase-3) of peripheral blood leukocytes in order to produce superoxide and proinflammatory cytokines, which can further aggravate airway inflammation [79]. On the other hand, it is worth mentioning that the airway smooth muscle (ASM) not only has contractile properties but also is involved in the pathogenesis of asthma, producing inflammatory mediators. Human neutrophil elastase is a mitogen which activates ASM cells through extracellular signal-regulated kinase (ERK) signaling pathway [80]. Other interesting study shows that the allergic stimulation of airways provokes the release of elastase, tissue kallikrein (TK) and reactive oxygen species (ROS), reducing AAT activity and contributing to airway hyper-reactivity (AHR) [81]. Moreover, the bronchoconstriction caused by elastase, high-molecular-weight kininogen and ROS and AHR induced by both ROS and antigen was stopped thanks to the application of 10 mg of recombinant AAT, suggesting the key role of AAT in regulating

airway responsiveness [82]. In conclusion, the positive effects of AAT augmentation therapy observed in this case support the hypothesis of a proteinase-antiproteinase imbalance in the pathogenesis of asthma, reaffirming the need for further studies on the mechanisms of this bronchial disease and the efficacy of AAT augmentation therapy in selected AAT deficiency subjects with refractory asthma.

In summary, all these 12 cases should promote further laboratory studies in animals and humans as well as larger clinical trials in order to determine the strong efficacy of AAT augmentation therapy in diseases other than pulmonary emphysema, especially as a powerful anti-inflammatory agent in processes such as fibromyalgia, vasculitis, panniculitis and bronchial asthma.

Acknowledgements

The authors would like to acknowledge the expert editorial assistance of Ms Jimena Blanco Fueyo (BA, MA *Université de Genève*, Switzerland; Pg. D. *United Nations Institute for Training and Research*).

The authors are also indebted to Ms Sue Edelstein for her invaluable collaboration in the graphic design of this manuscript (Department of Arts and Photography of the National Institute of Environmental Health Sciences (NIEHS), Research Triangle Park, NC, U.S.).

Author details

¹Biomedical Research Office (OIB-FICYT), Rosal, 7. 33009 Oviedo. Principality of Asturias. Spain. ²Hospital Universitario Arnau de Vilanova. Avda. Alcalde Rovira Roure 80. 25198. Institut de Recerca Biomèdica de Lleida (IRB). Lleida. CIBERES Instituto Salud Carlos III Madrid. Spain. ³National Institute of Environmental Health Sciences, Research Triangle Park, NC 27709-2233 USA.

Authors' contributions

IB conceived of the study, participated in its design and coordination, carried out data collection and analysis and drafted the manuscript. FS and BL carried out data collection and participated in the design and analysis of the study. All authors read and approved the final manuscript.

Competing interests

The authors declare that they have no competing interests.

Received: 21 September 2010 Accepted: 12 April 2011

Published: 12 April 2011

References

1. Blanco I, de Serres FJ, Fernandez-Bustillo E, Lara B, Miravittles M: Estimated numbers and prevalence of P1*S and P1*Z alleles of alpha1-antitrypsin deficiency in European countries. *Eur Respir J* 2006, **27**(1):77-84.
2. de Serres FJ, Blanco I, Fernández-Bustillo E: P1 S and P1 Z alpha-1 antitrypsin deficiency worldwide. A review of existing genetic epidemiological data. *Monaldi Arch Chest Dis* 2007, **67**(4):184-208.
3. American Thoracic Society/European Respiratory Society Statement: standards for the diagnosis and management of individuals with alpha1-antitrypsin deficiency. *Am J Respir Crit Care Med* 2003, **168**(7):818-900.
4. Janciauskiene S, Stevens T, Blanco I: New insights into the biology of alpha1-antitrypsin and its role in chronic obstructive pulmonary disease. *Current Respiratory Medicine Reviews* 2007, **3**:147-158.
5. Janoff A: Inhibition of human granulocyte elastase by serum alpha-1-antitrypsin. *Am Rev Respir Dis* 1972, **105**(1):121-2.
6. Lieberman J, Kaneshiro W: Inhibition of leukocytic elastase from purulent sputum by alpha 1-antitrypsin. *J Lab Clin Med* 1972, **80**(1):88-101.
7. Travis J, Salvesen GS: Human plasma proteinase inhibitors. *Annu Rev Biochem* 1983, **52**:655-709.

8. Potempa J, Korzus E, Travis J: **The serpin superfamily of proteinase inhibitors: structure, function and regulation.** *J Biol Chem* 1994, **269**(23):15957-60.
9. Stockley RA, Burnett D: **Alpha₁-antitrypsin and leukocyte elastase in infected and noninfected sputum.** *Am Rev Respir Dis* 1979, **120**(5):1081-6.
10. Korkmaz B, Attucci S, Jourdan ML, Juliano L, Gauthier F: **Inhibition of neutrophil elastase by alpha₁-protease inhibitor at the surface of human polymorphonuclear neutrophils.** *J Immunol* 2005, **175**(5):3329-3338.
11. Duranton J, Bieth JG: **Inhibition of proteinase 3 by [alpha₁]-antitrypsin in vitro predicts very fast inhibition in vivo.** *Am J Respir Cell Mol Biol* 2003, **29**(1):57-61.
12. Rao NV, Wehner NG, Marshall BC, Gray WR, Gray BH, Hoidal JR, Characterization of proteinase-3 (PR-3), a neutrophil serine proteinase: **Structural and functional properties.** *J Biol Chem* 1991, **266**(15):9540-8.
13. Borregaard N, Jensen HS, Bjerrum OW: **Prevention of tissue damage: inhibition of myeloperoxidase mediated inactivation of alpha₁-proteinase inhibitor by N-acetyl cysteine, glutathione, and methionine.** *Agents Actions* 1987, **22**(3-4):255-60.
14. Campbell EJ, Senior RM, McDonald JA, Cox DL: **Proteolysis by neutrophils. Relative importance of cell-substrate contact and oxidative inactivation of proteinase inhibitors in vitro.** *J Clin Invest* 1982, **70**(4):845-52.
15. Duranton J, Adam C, Bieth JG: **Kinetic mechanism of the inhibition of cathepsin G by alpha₁-antichymotrypsin and alpha₁-proteinase inhibitor.** *Biochemistry* 1998, **37**(32):11239-45.
16. Rowley PT, Sevilla ML, Schwartz H: **Serum alpha₁-antitrypsin types: elastase inhibition versus trypsin inhibition.** *Hum Hered* 1974, **24**(5-6):472-81.
17. He SH, Chen HQ, Zheng J: **Inhibition of trypsin and chymase induced nucleated cell infiltration by proteinase inhibitors.** *Acta Pharmacol Sin* 2004, **25**(12):1677-84.
18. He SH, Xie H, Zhang XJ, Wang XJ: **Inhibition of histamine release from human mast cells by natural chymase inhibitors.** *Acta Pharmacol Sin* 2004, **25**(6):822-6.
19. He SH, Xie H: **Inhibition of trypsin release from human colon mast cells by protease inhibitors.** *World J Gastroenterol* 2004, **10**(3):332-6.
20. Pemberton AD, Belham CM, Huntley JF, Plevin R, Miller HR: **Sheep mast cell proteinase-1, a serine proteinase with both trypsin- and chymase-like properties, is inhibited by plasma proteinase inhibitors and is mitogenic for bovine pulmonary artery fibroblasts.** *Biochem J* 1997, **323**(Pt 3):719-25.
21. Beatty K, Bieth J, Travis J: **Kinetics of association of serine proteinases with native and oxidized alpha₁-proteinase inhibitor and alpha₁-antichymotrypsin.** *J Biol Chem* 1980, **255**(9):3931-4.
22. Cohen AB: **The interaction of alpha₁-antitrypsin with chymotrypsin, trypsin and elastase.** *Biochim Biophys Acta* 1975, **391**(1):193-200.
23. Patston PA, Roodi N, Schifferli JA, Bischoff R, Courtney M, Schapira M: **Reactivity of alpha₁-antitrypsin mutants against proteolytic enzymes of the kallikrein-kinin, complement, and fibrinolytic systems.** *J Biol Chem* 1990, **265**(18):10786-91.
24. Luo LY, Jiang W: **Inhibition profiles of human tissue kallikreins by serine protease inhibitors.** *Biol Chem* 2006, **387**(6):813-6.
25. Obiezu CV, Michael IP, Levesque MA, Diamandis EP: **Human kallikrein 4: enzymatic activity, inhibition, and degradation of extracellular matrix proteins.** *Biol Chem* 2006, **387**(6):749-59.
26. Patston PA, Roodi N, Schifferli JA, Bischoff R, Courtney M, Schapira M, Clemmensen I, Christensen F: **Inhibition of urokinase by complex formation with human alpha₁-antitrypsin.** *Biochim Biophys Acta* 1976, **429**(2):591-9.
27. Mast AE, Enghild JJ, Pizzo SV, Salvesen G: **Analysis of the plasma elimination kinetics and conformational stabilities of native, proteinase-complexed, and reactive site cleaved serpins: comparison of alpha₁-proteinase inhibitor, alpha₁-antichymotrypsin, antithrombin III, alpha₂-antiplasmin, angiotensinogen, and ovalbumin.** *Biochemistry* 1991, **30**(6):1723-30.
28. Gallimore MJ: **Serum inhibitors in fibrinolysis.** *Br J Haematol* 1975, **31**(2):217-31.
29. Stefansson S, Yepes M, Gorlatova N, Day DE, Moore EG, Zabaleta A, McMahon GA, Lawrence DA: **Mutants of plasminogen activator inhibitor-1 designed to inhibit neutrophil elastase and cathepsin G are more effective in vivo than their endogenous inhibitors.** *J Biol Chem* 2004, **279**(29):29981-7.
30. Spencer LT, Paone G, Krein PM, Rouhani FN, Rivera-Nieves J, Brantly ML: **Role of human neutrophil peptides in lung inflammation associated with alpha₁-antitrypsin deficiency.** *Am J Physiol Lung Cell Mol Physiol* 2004, **286**(3):L514-20.
31. Wencker M, Brantly ML: **Cytotoxic concentrations of alpha-defensins in the lungs of individuals with alpha₁-antitrypsin deficiency and moderate to severe lung disease.** *Cytokine* 2005, **32**(1):1-6.
32. Mahrus S, Kisiel W, Craik CS: **Granzyme M is a regulatory protease that inactivates proteinase inhibitor 9, an endogenous inhibitor of granzyme B.** *J Biol Chem* 2004, **279**(52):54275-82.
33. Janciauskiene S, Nita I, Subramaniam D, Li Q, Lancaster JR Jr, Matalon S: **Alpha₁-antitrypsin inhibits the activity of the matrix metalloproteinase catalytic domain in vitro.** *Am J Respir Cell Mol Biol* 2008, **39**(6):631-7.
34. Lazrak A, Nita I, Subramaniam D, Wei S, Song W, Ji HL, Janciauskiene S, Matalon S: **Alpha₁(1)-antitrypsin inhibits epithelial Na⁺ transport in vitro and in vivo.** *Am J Respir Cell Mol Biol* 2009, **41**(3):261-70.
35. Petrache I, Fijalkowska I, Zhen L, Medler TR, Brown E, Cruz P, Choe KH, Taraseviciene-Stewart L, Scerbavicius R, Shapiro L, Zhang B, Song S, Hicklin D, Voelkel NF, Flotte T, Tuder RM: **A novel antiapoptotic role for alpha₁-antitrypsin in the prevention of pulmonary Emphysema.** *Am J Respir Crit Care Med* 2006, **173**(11):1222-8.
36. Kalis M, Kumar R, Janciauskiene S, Salehi A, Cilio CM: **alpha₁-antitrypsin, old dog, new tricks. Alpha₁-antitrypsin exerts in vitro anti-inflammatory activity in human monocytes by elevating cAMP.** *J Biol Chem* 2007, **282**(12):8573-82.
37. Subramaniam D, Virtala R, Pawlowski K, Clausen IG, Warkentin S, Stevens T, Janciauskiene S: **TNF-alpha-induced self expression in human lung endothelial cells is inhibited by native and oxidized alpha₁-antitrypsin.** *Int J Biochem Cell Biol* 2008, **40**(2):258-71.
38. Kalis M, Kumar R, Janciauskiene S, Salehi A, Cilio CM: **alpha₁-antitrypsin enhances insulin secretion and prevents cytokine-mediated apoptosis in pancreatic beta-cells.** *Islets* 2010, **2**(3):185-9.
39. Stoller JK, Aboussouan LS: **Alpha₁-antitrypsin deficiency.** *Lancet* 2005, **365**(9478):2225-36.
40. Mahr AD, Edberg JC, Stone JH, Hoffman GS, St Clair EW, Specks U, Dellaripa PF, Seo P, Spiera RF, Rouhani FN, Brantly ML, Merkel PA: **Alpha₁(1)-antitrypsin deficiency-related alleles Z and S and the risk of Wegener's granulomatosis.** *Arthritis Rheum* 2010, **62**(12):3760-7.
41. Wewers MD, Casolaro MA, Sellers SE, Swayze SC, McPhaul KM, Wittes JT, Crystal RG: **Replacement therapy for alpha₁-antitrypsin deficiency associated with emphysema.** *N Engl J Med* 1987, **316**(17):1055-62.
42. Gadek JE, Klein HG, Holland PV, Crystal RG: **Replacement therapy of alpha₁-antitrypsin deficiency. Reversal of protease-antiprotease imbalance within the alveolar structures of PiZ subjects.** *J Clin Invest* 1981, **68**(5):1158-65.
43. Seersholm N, Wencker M, Banik N, Viskum K, Dirksen A, Kok-Jensen A, Konietzko N: **Does alpha₁-antitrypsin augmentation therapy slow the annual decline in FEV1 in patients with severe hereditary alpha₁-antitrypsin deficiency? Wissenschaftliche Arbeitsgemeinschaft zur Therapie von Lungenerkrankungen (WATL) alpha₁-AT study group.** *Eur Respir J* 1997, **10**(10):2260-3.
44. No authors listed: **Survival and FEV1 decline in individuals with severe deficiency of alpha₁-antitrypsin. The Alpha-1-Antitrypsin Deficiency Registry Study Group.** *Am J Respir Crit Care Med* 1998, **158**(1):49-59.
45. Dirksen A, Dijkman JH, Madsen F, Stoel B, Hutchison DC, Ulrik CS, Skovgaard LT, Kok-Jensen A, Rudolphus A, Seersholm N, Vrooman HA, Reiber JH, Hansen NC, Heckscher T, Viskum K, Stolk J: **A randomized clinical trial of alpha₁(1)-antitrypsin augmentation therapy.** *Am J Respir Crit Care Med* 1999, **160**(5 Pt 1):1468-72.
46. Wencker M, Fuhrmann B, Banik N, Konietzko N, Wissenschaftliche Arbeitsgemeinschaft zur Therapie von Lungenerkrankungen: **Longitudinal follow-up of patients with alpha₁(1)-protease inhibitor deficiency before and during therapy with IV alpha₁(1)-protease inhibitor.** *Chest* 2001, **119**(3):737-44.
47. Dirksen A, Piitulainen E, Parr DG, Deng C, Wencker M, Shaker SB, Stockley RA: **Exploring the role of CT densitometry: a randomised study of augmentation therapy in alpha₁-antitrypsin deficiency.** *Eur Respir J* 2009, **33**(6):1345-53.
48. [No authors listed]: **Current status of alpha₁-antitrypsin replacement therapy: recommendations for the management of patients with severe hereditary deficiency.** Ad Hoc Committee on Alpha-1-Antitrypsin Replacement Therapy of the Standards Committee, Canadian Thoracic Society. *CMAJ* 1992, **146**(6):841-4.

49. Vidal R, Blanco I, Casas F, Jardí R, Miravittles M, Committee on the National Registry of Individuals with Alpha-1 Antitrypsin Deficiency: [Guidelines for the diagnosis and management of alpha-1 antitrypsin deficiency]. *Arch Bronconeumol* 2006, **42**(12):645-59.
50. Göttsche PC, Johansen HK: Intravenous alpha-1 antitrypsin augmentation therapy for treating patients with alpha-1 antitrypsin deficiency and lung disease. *Cochrane Database Syst Rev* 2010, **7**:CD007851.
51. Tonelli AR, Brantly ML: Augmentation therapy in alpha-1 antitrypsin deficiency: advances and controversies. *Thorax* 2010, **65**(5):329-332.
52. Stockley RA, Parr DG, Piitulainen E, Stolk J, Stoel BC, Dirksen A: Therapeutic efficacy of alpha-1 antitrypsin augmentation therapy on the loss of lung tissue: an integrated analysis of 2 randomised clinical trials using computed tomography densitometry. *Respir Res* 2010, **11**:136.
53. Shapiro L, Pott GB, Ralston AH: Alpha-1-antitrypsin inhibits human immunodeficiency virus type 1. *FASEB J* 2001, **15**(1):115-122.
54. Hadzic R, Nita I, Tassidis H, Riesbeck K, Wingren AG, Janciauskiene S: Alpha-1-antitrypsin inhibits *Moraxella catarrhalis* MID protein-induced tonsillar B cell proliferation and IL-6 release. *Immunol Lett* 2006, **102**(2):141-7.
55. Knappstein S, Ide T, Schmidt MA, Heusipp G: Alpha 1-antitrypsin binds to and interferes with functionality of EspB from atypical and typical enteropathogenic *Escherichia coli* strains. *Infect Immun* 2004, **72**(8):4344-50.
56. Cantin AM, Woods DE: Aerosolized prolactin suppresses bacterial proliferation in a model of chronic *Pseudomonas aeruginosa* lung infection. *Am J Respir Crit Care Med* 1999, **160**(4):1130-5.
57. Chan ED, Kaminska AM, Gill W, Chmura K, Feldman NE, Bai X, Floyd CM, Fulton KE, Huitt GA, Strand MJ, Iseman MD, Shapiro L: Alpha-1-antitrypsin (AAT) anomalies are associated with lung disease due to rapidly growing mycobacteria and AAT inhibits *Mycobacterium abscessus* infection of macrophages. *Scand J Infect Dis* 2007, **39**(8):690-6.
58. Lushbaugh WB, Kairalla AB, Hofbauer AF, Arnaud P, Cantey JR, Pittman FE: Inhibition of *Entamoeba histolytica* cytotoxin by alpha 1 antiprotease and alpha 2 macroglobulin. *Am J Trop Med Hyg* 1981, **30**(3):575-85.
59. Forney JR, Yang S, Healey MC: Antagonistic effect of human alpha-1-antitrypsin on excystation of *Cryptosporidium parvum* oocysts. *J Parasitol* 1997, **83**(4):771-4.
60. Daemen MA, Heemskerck VH, van't Veer C, Denecker G, Wolfs TG, Vandenaabeele P, Buurman WA: Functional protection by acute phase proteins alpha(1)-acid glycoprotein and alpha(1)-antitrypsin against ischemia/reperfusion injury by preventing apoptosis and inflammation. *Circulation* 2000, **102**(12):1420-6.
61. Dowd SK, Rodgers GC, Callen JP: Effective treatment with alpha 1-protease inhibitor of chronic cutaneous vasculitis associated with alpha 1-antitrypsin deficiency. *J Am Acad Dermatol* 1995, **33**(5 Pt 2):913-6.
62. Smith KC, Pittelkow MR, Su WP: Panniculitis associated with severe alpha 1-antitrypsin deficiency. Treatment and review of the literature. *Arch Dermatol* 1987, **123**(12):1655-61.
63. Furey NL, Golden RS, Potts SR: Treatment of alpha-1-antitrypsin deficiency, massive edema, and panniculitis with alpha-1 protease inhibitor. *Ann Intern Med* 1996, **125**(8):699.
64. O'Riordan K, Blei A, Rao MS, Abecassis M: alpha 1-antitrypsin deficiency-associated panniculitis: resolution with intravenous alpha 1-antitrypsin administration and liver transplantation. *Transplantation* 1997, **63**(3):480-2.
65. Chowdhury MM, Williams EJ, Morris JS, Ferguson BJ, McGregor AD, Hedges AR, Stamatakis JD, Pope FM: Severe panniculitis caused by homozygous ZZ alpha1-antitrypsin deficiency treated successfully with human purified enzyme (Prolactin). *Br J Dermatol* 2002, **147**(6):1258-61.
66. Kjus T, Lützow-Holm C, Christensen OB: Treatment of panniculitis associated with alpha-1-antitrypsin deficiency with alpha-1-protease inhibitor. *Br J Dermatol* 2002, **147**(6):1258-61.
67. Gross B, Grebe M, Wencker M, Stoller JK, Bjursten LM, Janciauskiene S: New Findings in PiZZ alpha(1)-Antitrypsin Deficiency-Related Panniculitis. Demonstration of Skin Polymers and High Dosing Requirements of Intravenous Augmentation Therapy. *Dermatology* 2009, **218**(4):370-5.
68. Blanco I, Canto H, de Serres FJ, Bustillo EF, Rodríguez MC: Alpha-1-antitrypsin replacement therapy efficiently controls fibromyalgia symptoms in two Pi ZZ alpha-1-antitrypsin deficiency patients. *J Rheumatol* 2004, **31**(10):2082-5.
69. Blanco I, Astudillo A, Domínguez F, Janciauskiene S, Cárcaba V, Gallo C, Canto H, de Serres FJ, Bustillo EF: Intravenous Infusions of Purified Alpha 1-Antitrypsin Effectively Controls Symptoms and Reverts Muscle Biopsy Changes in an MZ-Alpha-1 Antitrypsin Deficiency and Fibromyalgia Syndrome Patient. *J Musculoske Pain* 2010, **18**(2):167-72.
70. Blanco I, Canto H, Flores J, Cambor C, Cárcaba V, de Serres FJ, Janciauskiene S, Bustillo EF: Long-term augmentation therapy with alpha-1 antitrypsin in an MZ-AAT severe persistent asthma. *Monaldi Arch Chest Dis* 2008, **69**(4):178-82.
71. Jenicek M: Clinical case reporting in Evidence-based Medicine. Oxford University Press Inc, 18 Madison Avenue, NY10016, 2 2001.
72. Fernández-Torres R, García-Silva J, Robles O, Otero A, Vázquez MA, Fonseca E: Alfa-1-antitrypsin deficiency panniculitis acquired after liver transplant and successfully treated with retransplant. *J Am Acad Dermatol* 2009, **60**(4):715-6.
73. de Oliveira P, Paz-Melgar L, Takahashi MD, Nico MM, Rivitti EA, Mendrone A Jr, Tatsui NH: Alpha-1-antitrypsin deficiency associated with panniculitis treated with plasma exchange therapy. *Int J Dermatol* 2004, **43**(9):693-7.
74. Viraben R, Massip P, Dicozanzo B, Mathieu C: Necrotic panniculitis with alpha-1-antitrypsin deficiency. *J Am Acad Dermatol* 1986, **14**(4):684-687.
75. Blanco I, Arbesú D, Al Kassam D, De Serres F, Fernández-Bustillo E, Rodríguez Menéndez C: Alpha1-antitrypsin polymorphism in fibromyalgia patients from the Asturias Province in Northern Spain: A significantly higher prevalence of the Pi*Z deficiency allele in patients than in the general population. *J Musculoskel Pain* 2006, **14**(3):5-12.
76. Blanco I, Janciauskiene S, Nita I, Fernández-Bustillo E, Cárcaba V, Gallo C, Alvarez-Rico M, de Serres F, Bérizze N: Low plasma levels of Monocyte Chemoattractant Protein-1 (MCP-1), Tumor Necrosis Factor-alpha (TNF α), and Vascular Endothelial Growth Factor (VEGF) in patients with Alpha-1-Antitrypsin Deficiency-related Fibromyalgia. *Clin Rheumatol* 2010, **29**(2):189-97.
77. Blanco I, Bérizze N, Argüelles M, Cárcaba V, Fernández F, Janciauskiene S, Oikonomopoulou K, de Serres FJ, Fernández-Bustillo E, Hollenberg MD: Abnormal overexpression of mastocytes in skin biopsies of fibromyalgia patients. *Clin Rheumatol* 2010, **29**(12):1403-12.
78. Vignola AM, Bonanno A, Mirabella A, Riccobono L, Mirabella F, Profita M, Bellia V, Bousquet J, Bonsignore G: Increased levels of elastase and alpha1-antitrypsin in sputum of asthmatic patients. *Am J Respir Crit Care Med* 1998, **157**(2):505-11.
79. Hiraguchi Y, Nagao M, Hosoki K, Tokuda R, Fujisawa T: Neutrophil Proteases Activate Eosinophil Function in vitro. *Int Arch Allergy Immunol* 2008, **146**(Suppl 1):16-21.
80. Huang CD, Chen HH, Wang CH, Chou CL, Lin SM, Lin HC, Kuo HP: Human neutrophil-derived elastase induces airway smooth muscle cell proliferation. *Life Sci* 2004, **74**(20):2479-2492.
81. Forteza R, Botvinnikova Y, Ahmed A, Cortes A, Gundel RH, Wanner A, Abraham WM: The interaction of alpha 1-proteinase inhibitor and tissue kallikrein in controlling allergic ovine airway hyperresponsiveness. *Am J Respir Crit Care Med* 1996, **154**(1):36-42.
82. Scuri M, Botvinnikova Y, Lauro IT, Abraham WM: Recombinant alpha 1-proteinase inhibitor blocks antigen- and mediator-induced airway responses in sheep. *J Appl Physiol* 2002, **93**(6):1900-06.

doi:10.1186/1750-1172-6-14

Cite this article as: Blanco *et al.*: Efficacy of alpha1-antitrypsin augmentation therapy in conditions other than pulmonary emphysema. *Orphanet Journal of Rare Diseases* 2011 **6**:14.